

PATIENT

Betty Ann Edmonds

SPECIES

Canine

BREED

Heeler Mix

SEX

FS

AGE

3 years

WEIGHT

53.6 #

INTERPRETED BY

Remo Lobetti, BVSc,
MMedVet (Med), PhD, Dipl.
ECVIM

IMAGING PERFORMED BY

Jenna Walsh

HOSPITAL NAME

West Hills Animal Hospital

REFERRING VET

Dr Glaze

INVOICE

303618

DATE

12/3/22

PRESENTING CLINICAL SIGNS

History: Intermittent vomiting, vomits bile in the morning. On Science Diet D/D Potato and Duck diet.

Physical Examination: N/A.

Urinalysis: N/A.

CBC: N/A.

Serum Biochemistry: N/A.

Radiographic Findings: N/A.

ULTRASONOGRAPHIC EXAMINATION OF THE ABDOMEN

Urinary System

Full urinary bladder with a normal appearance and thickness of the wall. Normal anechoic urine with no sediment or uroliths evident.

Normal trigone area, proximal urethra, and iliac blood vessels.

Normal iliac lymph nodes. Ureters not visualized.

Normal renal size (left 5.6 cm, right 5.5 cm), echogenic appearance, cortico-medullary differentiation, pelvis, and capsule.

Reproductive System

N/A.

Adrenal Glands

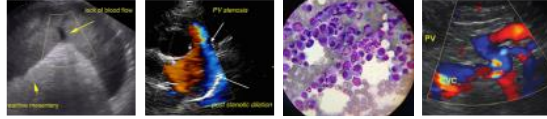
Normal shape, echogenic appearance, position, and size. Left 2.39 x 0.62/0.57 cm, right 2.35 x 0.48 cm.

Spleen

Normal size and echogenic appearance. Smooth homogenous parenchyma, regular curvilinear capsule, and normal vasculature. No evidence of inflammatory, neoplastic, infarction, or infiltrative changes noted.

Liver

Normal size, echogenic appearance, portal markings, and regular curvilinear capsule. No nodules or masses evident. Small gall bladder containing normal anechoic bile. Normal thickness and echogenic appearance of the gall bladder wall. Normal bile duct.



PATIENT

Betty Ann Edmonds

SPECIES

Canine

BREED

Heeler Mix

SEX

FS

AGE

3 years

WEIGHT

53.6 #

INTERPRETED BY

Remo Lobetti, BVSc,
MMedVet (Med), PhD, Dipl.
ECVIM

IMAGING PERFORMED BY

Jenna Walsh

HOSPITAL NAME

West Hills Animal Hospital

REFERRING VET

Dr Glaze

INVOICE

303618

DATE

12/3/22

Gastrointestinal

Normal appearance of the stomach, duodenum, small intestine, ileo-cecal junction, and colon with no loss of layering, normal wall thickness and peristaltic activity, and no distension of the lumen.

Pancreas

Normal size and echogenic appearance. Regular capsule. Normal echogenic appearance of the mesentery and fat surrounding the pancreas.

Free Abdomen

No mesenteric lymphadenomegaly.
No ascites.

ULTRASONOGRAPHIC FINDINGS

Primary Findings:

- None.

Secondary Findings:

- None.

INTERPRETATION OF THE FINDINGS & FURTHER RECOMMENDATIONS

Normal ultrasound examination of the abdomen.

With the presenting clinical signs, inflammatory disease, parasitic enteritis, dietary hypersensitivity, and bilious vomiting syndrome needs to be considered.

Further assessment would be fecal analysis, cobalamin assay, and endoscopy of the upper GI tract with biopsies.

The information and recommendations provided are based on the images presented by the referring veterinarian. No evaluation can be communicated regarding pathology that was not visible in the image/video clips provided.

Thank you for this referral. If the clinical or image interpretation does not parallel your findings or if I can be of any further assistance, please contact me.

Remo Lobetti, BVSc, MMedVet (Med), PhD, Dipl. ECVIM (Internal Medicine)
rlobetti@mweb.co.za